
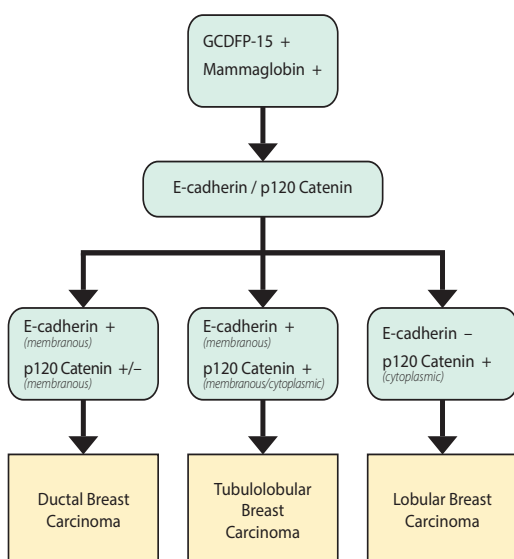


# What's your panel?

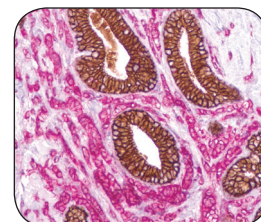


*p120 Catenin points you in the right direction.*



**A**nti-p120 Catenin and E-cadherin can be used in the differentiation of lobular and ductal carcinoma of the breast. E-cadherin is expressed in a membranous pattern in the case of ductal carcinoma. On the other hand, in the case of lobular carcinoma, p120 Catenin expression occurs in the cell cytoplasm and not in the cell membrane. E-cadherin expression is lost in lobular carcinoma. Tubulolobular carcinoma of the breast strongly expresses both membranous E-cadherin and membranous p120 Catenin.

Cell Marque believes that diagnostic panels generally serve as a helpful guideline to pathologists. Please refer to additional panels in our Volume 10 Reference Guide.



*Above: E-cadherin + p120 Catenin*